

# Vascular Ring and Recurrent Pneumonia

Priyadarshini Arunakumar, DM; Anoop Ayyappan, MD

Sree Chitra Tirunal Institute for Medical Sciences and Technology, Trivandrum, India

**Abstract:** We report on an 11-year-old girl who presented with a history of recurrent pneumonia since early childhood and symptoms suggestive of gastroesophageal reflux. Her initial workup for recurrent pneumonia was negative. Echocardiogram did not reveal any intracardiac lesion but raised suspicion of abnormality of aortic arch — presence of 4 neck vessels instead of the typical 3. Computed tomography (CT) angiogram was subsequently performed, and it revealed the presence of double aortic arch, with a larger right-sided arch. A sudden taper in esophageal caliber was noted, suggesting esophageal compression, which may have exacerbated the respiratory symptoms. CT also showed bilateral lower lobe consolidation. This report shows that vascular ring should be considered, even in the absence of stridor, as a cause of recurrent pneumonia. Surgical treatment aims at resection of the lesser arch to relieve compressive symptoms.

VASCULAR DISEASE MANAGEMENT 2017;14(11):E238-E239

**Key words:** vascular ring, recurrent pneumonia, aortic arch

An 11-year old girl presented with history of recurrent pneumonia since early childhood and symptoms suggestive of gastroesophageal reflux. She was sent for cardiac evaluation as a part of a workup for persistent respiratory symptoms.

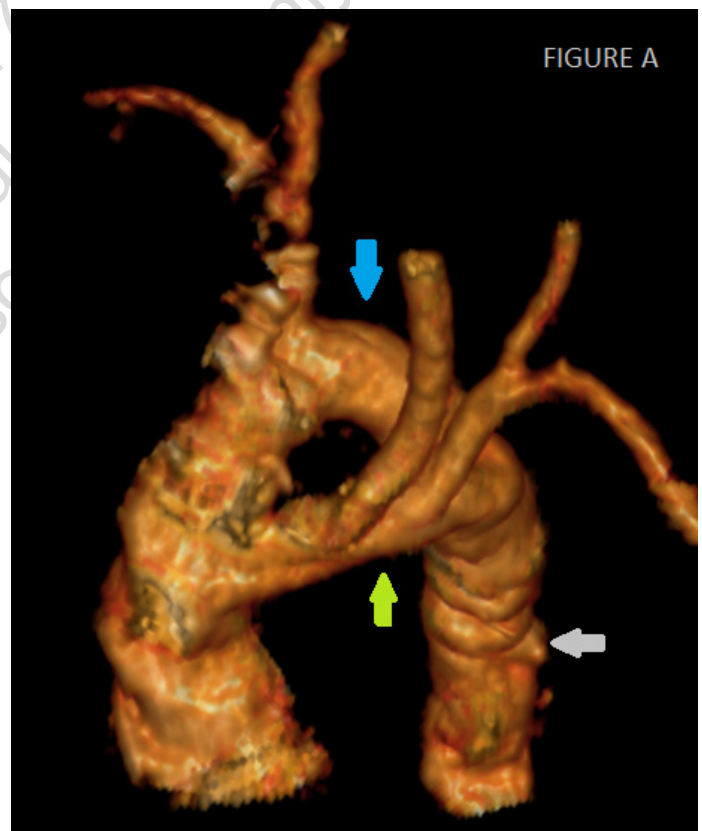Her physical examination and electrocardiogram results were essentially unremarkable. Chest x-ray was suggestive of right aortic arch with consolidation in the right lower zone. Echocardiogram did not reveal any intracardiac lesion but raised suspicion of abnormality of aortic arch—presence of 4 neck vessels instead of the typical 3 vessels. Computed tomography (CT) angiogram was subsequently done, and it revealed the presence of double aortic arch (**Figure A**), with a larger right-sided arch (blue arrow) and smaller left arch (green arrow) joining to form the descending aorta (grey arrow). The right subclavian and common carotid arteries arose from the right arch (**Figure B2**) and, similarly, left subclavian and common carotid arteries from the left arch (**Figure B1**). A sudden taper (blue arrow in **Figure C2**) in the esophageal caliber was noted, suggesting esophageal compression, which may have exacerbated the respiratory symptoms.

CT also showed bilateral lower lobe consolidation (yellow stars in **Figure C3**). In view of her symptoms, surgery is planned with an aim to resect the lesser of the arches. Vascular rings should be considered in patients with persistent respiratory symptoms in the absence of any intracardiac lesion, after an initial workup for recurrent pneumonia. ■

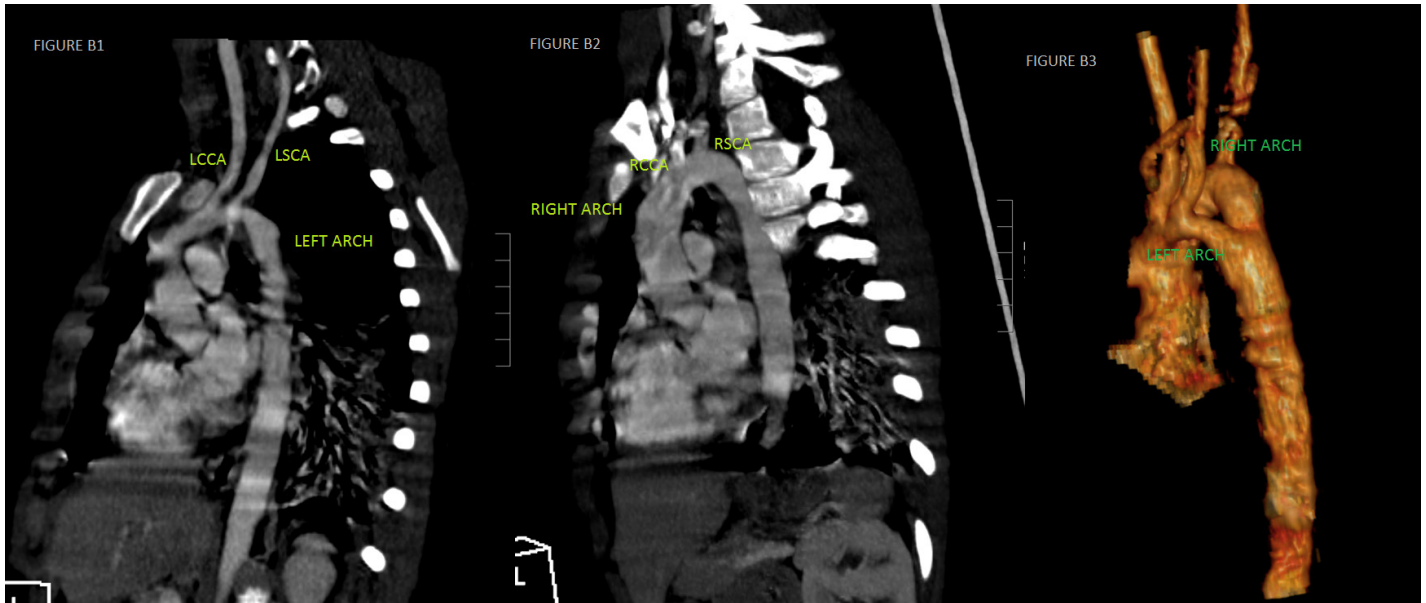
*Disclosure:* The authors have completed and returned the ICMJE Form for Disclosure of Potential Conflicts of Interest. The authors report no conflicts of interest regarding the content herein.

*Manuscript submitted October 10, 2017; accepted October 16, 2017.*

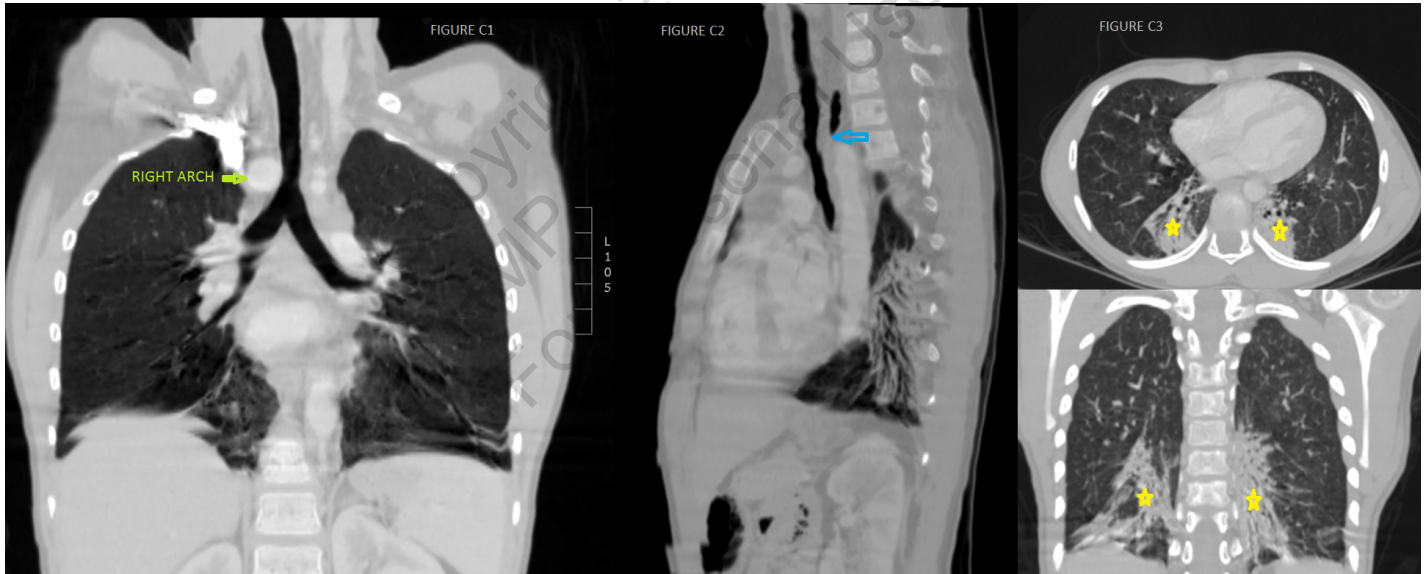
*Address for correspondence:* Priyadarshini Arunakumar, DM; Sree Chitra Tirunal Institute for Medical Sciences and Technology, Trivandrum, India. Email: priya\_arun\_2000@yahoo.com



**Figure A.** 3D VRT (volume rendered technique) image in left superior oblique projection showing double aortic arch with anterior (left) aortic arch shown by yellow arrow and posterior (right) aortic arch shown by blue arrow) joining together to form descending thoracic aorta (gray arrow).



**Figure B.** (1) Sagittal CT angiogram image showing left aortic arch, which is relatively hypoplastic with origins of LCCA (left common carotid artery) and LSCA (left subclavian artery). (2) Sagittal CT angiogram image showing right aortic arch which is normal in caliber, with origins of RCCA (right common carotid artery) and RSCA (right subclavian artery). (3) 3D VRT image showing double aortic arch with anterior left arch and posterior right arch.



**Figure C.** (1 and 2) Coronal and sagittal minimum intensity projection image showing absence of tracheal compression by the double aortic arch. Note the abrupt tapering of the esophagus (blue arrow) just proximal to the union of both arches. (3) Axial and coronal maximum intensity projection image showing evidence of aspiration in bilateral lower lobar basal segments (yellow stars).